



Congress of
Neurological
Surgeons



April 23, 2018

Josiah Morse, MPH, Program Director
Washington State Healthcare Authority
Health Technology Assessment Program
P.O. Box 42712
Olympia, WA 98504-2712

**RE: Washington State Health Care Authority 2018 Health Technology Topic Selection –
Sacroiliac Joint Fusion Surgery**

Dear Mr. Morse:

On behalf of the American Association of Neurological Surgeons (AANS), Congress of Neurological Surgeons (CNS), AANS/CNS Joint Section on Disorders of the Spine and Peripheral Nerves (DSPN), International Society for the Advancement of Spine Surgery (ISASS) and Washington State Association of Neurological Surgeons (WSANS), we are writing to submit comments in response to the Washington State Health Care Authority's 2018 health technology assessment topic selection, specifically related to sacroiliac joint fusion surgery.

Thank you for the opportunity to provide comments on the 2018 health technology assessment topic selection. We agree with the Director's decision to select sacroiliac joint fusion surgery as a topic for the health technology assessment program in 2018 and believe the body of existing literature warrants coverage of the procedure by the Washington State Health Care Authority.

The sacroiliac joint (SIJ) is an accepted cause of chronic low back pain. Carefully performed surveys in outpatient spine clinics have shown that 15-30% of all chronic low back pain has a contribution from the SIJ.¹⁻⁴ The prevalence of SIJ pain is even higher in patients with low back pain after lumbar fusion.⁵⁻⁷ Patients with SIJ pain have difficulty sitting, driving, walking, ascending stairs, and turning over in bed. Patients with chronic SIJ pain have very poor quality of life,⁸ similar to patients with other common spine conditions treated surgically.⁹

Multiple non-surgical treatments for SIJ pain are available and consist of rest, oral medications, physical therapy, SIJ steroid injections and RF ablation of the lateral branches of the sacral nerve roots. No high-quality evidence suggests that any of these treatments are effective for long-lasting pain and disability relief. Some trials have shown RF ablation to be effective,^{10,11} while others have not.^{12,13} Most patients respond adequately to conservative treatment, however, there is a select group of patients who do not have satisfactory pain relief and may be functionally disabled. Surgical treatment is only considered an alternative for patients who have failed to respond to an adequate course of non-surgical treatment.

Fusion of the SIJ is not a new procedure. The procedure was performed as early as 1908¹⁴ and described in more detail in the 1920s.¹⁵ This traditional method of fusing the SIJ can provide pain relief, but recovery times and risks of complications are higher than a minimally invasive approach. Open SIJ fusion is reserved for those patients who are not candidates for the minimally invasive procedure.

In 2008, the U.S. Food and Drug Administration approved the first minimally invasive device for SIJ fusion. A Category I CPT® code to report the procedure went into effect on January 1, 2015. Currently there are over 22 devices of various shapes and sizes including cylindrical threaded, triangular, titanium cages, and allograft dowels that are indicated for minimally invasive SIJ fusion for patients with degeneration or disruption of the SIJ, the two most common causes of SIJ pain. It is important to note that we not support one technology over another. All devices are placed either inside or across the SIJ using a minimally invasive surgical approach. All devices perform the same mechanical function: stabilization of the SIJ resulting in bridging of the bone intended to alleviate pain. This minimally invasive approach affords surgeons the opportunity to perform a complex joint fusion procedure without the complications associated with a traditional open approach.

The published evidence supporting the safety and effectiveness of minimally invasive SIJ fusion is large and growing and includes two prospective, randomized controlled trials,^{16,17} large prospective multicenter studies,¹⁸⁻¹⁹ several long-term comparative cohorts,^{20,21} case series,²²⁻²⁸ prospective and retrospective single-center case series,²⁹⁻³¹ and systematic reviews.³²⁻³⁴ A pooled analysis of the three prospective trials (two RCTs) published in *Spine* showed remarkable treatment effects (i.e., superior pain, disability and quality of life improvement after surgery compared to non-surgical treatment).³⁵ Data derived from the US randomized trial also shows that SIJ fusion is cost-effective.³⁶ Radiographic fusion rates are >85% in most long-term published case series.^{27,29,37}

The diagnostic pathway for SIJ fusion includes a physical examination for SIJ pain consisting of key physical maneuvers that stress the SIJ and reproduce typical pain. These maneuvers are amongst the most accurate clinical examination tests.³⁸ For patients with positive physical examination signs, fluoroscopically guided SIJ block with local anesthetic is an accepted confirmatory diagnostic test³⁹ that is consistent with the philosophy of diagnostic tests in pain medicine.⁴⁰

In 2014, ISASS performed a review of the literature on SIJ fusion and issued a policy statement/coverage recommendation. The Society updated the guidelines in 2015 and 2016. The ISASS guidelines include a discussion on the SIJ as a pain generator, information on diagnosing the SIJ as the primary source of pain, a discussion of non-surgical and surgical treatment options, and recommended coverage criteria for minimally invasive SIJ fusion.

The ISASS policy statement (attached) recommends patients who have all the following criteria may be eligible for minimally invasive SIJ fusion:

- Significant SIJ pain that impacts quality of life or significantly limits activities of daily living;
- SIJ pain confirmed with at least 3 physical examination maneuvers that stress the SIJ and reproduce the patient's typical pain;
- Confirmation of the SIJ as a pain generator with $\geq 50\%$ acute decrease in pain upon fluoroscopically guided diagnostic intra-articular SIJ block using local anesthetic. Prospective trials have shown that patients with SIJ pain responses of 50-75% respond to MIS SIJ fusion as well as those with 75-100% acute responses;⁴¹
- Failure to respond to at least six months of non-surgical treatment consisting of non-steroidal anti-inflammatory drugs and physical therapy. Failure to respond means continued pain that interferes with activities of daily living and/or results in functional disability; and
- Additional or alternative diagnoses that could be responsible for the patient's ongoing pain or disability have been considered. Physicians should take into account that patients can have multiple pain generators and addressing just one pain generator may not adequately relieve disability or all back pain.

Minimally invasive SIJ fusion is NOT indicated for patients with the following:

- Less than six months of SIJ pain and/or functional impairment;
- Failure to pursue conservative treatment of the SIJ (unless contra-indicated);
- Pain not confirmed with response to intra-articular SIJ injections; or
- Presence of other pathology that would substantially prevent the patient from deriving benefit from SIJ fusion.

Of critical note is that the ISASS guidelines do not support or endorse the use of one device over another. ISASS specifically addresses this issue within the guidelines, "the ISASS coverage policy does not endorse a specific MIS SIJ system. There are numerous devices available that have all received 510(k) clearance for use in minimally invasive/percutaneous SIJ fusion/stabilization. The instrumentation utilized in a MIS SIJ procedure is the purview of surgeon preference."

Based upon the large and growing evidence base showing safety and efficacy of the procedure, we recommend coverage of SIJ fusion. We believe determination of non-coverage has several negative effects:

- First, non-coverage promotes lack of knowledge regarding the SIJ as a pain generator. This almost certainly results in misdiagnosis as other conditions. We are aware of unpublished evidence suggesting that lack of awareness can lead to inappropriate surgery, especially lumbar fusion. Misdirected surgery confers only risk and no benefit to the select group of patients seeking surgical solutions.
- Second, for those surgeons who recognize SIJ pain, non-coverage means that we cannot provide a surgical procedure that 1) routinely provides good clinical outcomes, and 2) is backed by substantial evidence. The result is that patients are forced to undergo continued conservative management. While SIJ injections and other non-surgical treatment may provide temporary pain and disability relief to some patients, these treatments do not address the underlying cause of pain. Moreover, without addressing pain, opioid use continues. In one case series, opioid use increased dramatically in patients with diagnosed SIJ pain whose insurance companies denied coverage.²¹ In contrast, those patients able to undergo SIJ fusion showed dramatic decreases in opioid use.
- Third, for health systems, non-coverage results in continued use of ineffective and expensive non-surgical treatment. Given that there is very little evidence to support the effectiveness of such non-surgical treatments, it is likely that the cost-effectiveness of such treatment is poor. Finally, an economic analysis suggests that ignoring the SIJ as a cause of chronic low back pain can be exceedingly expensive (>\$3000 per patient).⁴²

Thank you for your time and consideration of our comments. The evidence base shows that SIJ fusion provides substantial improvements in pain, disability and quality of life for select patients with chronic SIJ pain who are highly burdened by their disease.⁸ We recommend coverage of the procedure by the Washington State Health Care Authority.

Please contact us with questions or requests for additional information.

Sincerely,

American Association of Neurological Surgeons
Congress of Neurological Surgeons
AANS/CNS Joint Section on Disorders of the Spine and Peripheral Nerves
International Society for the Advancement of Spine Surgery
Washington State Association of Neurological Surgeons

Josiah Morse, MPH, Program Director
Multi-Specialty Society Letter Re: 2018 Health Technology Assessment Topic Selection –
Sacroiliac Joint Fusion Surgery
April 23, 2018
Page 5 of 15

Staff Contact:

Liz Vogt
Director of Health Policy & Advocacy
ISASS
Phone: (630) 375-1432
Email: liz@isass.org

Enclosures:

ISASS Policy Statement – Minimally Invasive Sacroiliac Joint Fusion (July 2016 Update)
Appendix: Summary of Key Publications

References

1. Sembrano JN and Polly DW: How often is low back pain not coming from the back? Spine 2009; **34**: E27-32.
2. Bernard TN and Kirkaldy-Willis WH: Recognizing specific characteristics of nonspecific low back pain. Clin. Orthop. 1987: 266–280.
3. Schwarzer AC, Aprill CN and Bogduk N: The sacroiliac joint in chronic low back pain. Spine 1995; **20**: 31–37.
4. Maigne JY, Aivaliklis A and Pfefer F: Results of sacroiliac joint double block and value of sacroiliac pain provocation tests in 54 patients with low back pain. Spine 1996; **21**: 1889–1892.
5. Maigne JY and Planchon CA: Sacroiliac joint pain after lumbar fusion. A study with anesthetic blocks. Eur. Spine J. 2005; **14**: 654–658.
6. DePalma MJ, Ketchum JM and Saullo TR: Etiology of Chronic Low Back Pain in Patients Having Undergone Lumbar Fusion. Pain Med. 2011; **12**: 732–739.
7. Liliang P-C, Lu K, Liang C-L, et al: Sacroiliac joint pain after lumbar and lumbosacral fusion: findings using dual sacroiliac joint blocks. Pain Med. Malden Mass 2011; **12**: 565–570.
8. Cher D, Polly D and Berven S: Sacroiliac joint pain: burden of disease. Med. Devices Auckl. NZ 2014; **7**: 73–81.

9. Cher DJ and Reckling WC: Quality of life in preoperative patients with sacroiliac joint dysfunction is at least as depressed as in other lumbar spinal conditions. *Med. Devices Evid. Res.* 2015; **8**: 395–403.
10. Cohen SP, Hurley RW, Buckenmaier CC, et al: Randomized placebo-controlled study evaluating lateral branch radiofrequency denervation for sacroiliac joint pain. *Anesthesiology* 2008; **109**: 279–288.
11. Patel N, Gross A, Brown L, et al: A randomized, placebo-controlled study to assess the efficacy of lateral branch neurotomy for chronic sacroiliac joint pain. *Pain Med.* 2012; **13**: 383–398.
12. Juch JNS, Maas ET, Ostelo RWJG, et al: Effect of Radiofrequency Denervation on Pain Intensity Among Patients With Chronic Low Back Pain: The Mint Randomized Clinical Trials. *JAMA* 2017; **318**: 68–81.
13. van Tilburg CWJ, Schuurmans FA, Stronks DL, et al: Randomized Sham-controlled Double-Blind Multicenter Clinical Trial to Ascertain the Effect of Percutaneous Radiofrequency Treatment for Sacroiliac Joint Pain: Three-month Results. *Clin. J. Pain* 2016. Available at: http://journals.lww.com/clinicalpain/Abstract/publishahead/Randomized_Sham_controlled_Double_Blind.99184.aspx.
14. Painter CF: Excision of the os innominatum. Arthrodesis of the sacro-iliac synchondrosis. *Boston Med. Surg. J.* 1908; **159**: 205–208.
15. Smith-Petersen MN: Arthrodesis of the sacroiliac joint. A new method of approach. *J. Bone Jt. Surg.* 1921; **3**: 400–405.
16. Polly DW, Swofford J, Whang PG, et al: Two-Year Outcomes from a Randomized Controlled Trial of Minimally Invasive Sacroiliac Joint Fusion vs. Non-Surgical Management for Sacroiliac Joint Dysfunction. *Int. J. Spine Surg.* 2016; **10**: Article 28.
17. Dengler J, Kools D, Pflugmacher R, et al: 1-Year Results of a Randomized Controlled Trial of Conservative Management vs. Minimally Invasive Surgical Treatment for Sacroiliac Joint Pain. *Pain Physician* 2017; **20**: 537–550.
18. Duhon BS, Bitan F, Lockstadt H, et al: Triangular Titanium Implants for Minimally Invasive Sacroiliac Joint Fusion: 2-Year Follow-Up from a Prospective Multicenter Trial. *Int. J. Spine Surg.* 2016; **10**: Article 13.
19. Araghi A, et al: Pain and Opioid use Outcomes Following Minimally Invasive Sacroiliac Joint Fusion with Decortication and Bone Grafting: The EVoluSIon Clinical Trial. *TOOJ* 2017, 11, 1440-1448.

20. Graham Smith A, Capobianco R, Cher D, et al: Open versus minimally invasive sacroiliac joint fusion: a multi-center comparison of perioperative measures and clinical outcomes. *Ann. Surg. Innov. Res.* 2013; **7**: 14.
21. Vanaclocha V, Herrera JM, Sáiz-Sapena N, et al: Minimally Invasive Sacroiliac Joint Fusion, Radiofrequency Denervation, and Conservative Management for Sacroiliac Joint Pain: 6-Year Comparative Case Series. *Neurosurgery* 2017.
22. Sachs D and Capobianco R: One year successful outcomes for novel sacroiliac joint arthrodesis system. *Ann. Surg. Innov. Res.* 2012; **6**: 13.
23. Cummings J Jr and Capobianco RA: Minimally invasive sacroiliac joint fusion: one-year outcomes in 18 patients. *Ann. Surg. Innov. Res.* 2013; **7**: 12.
24. Gaetani P, Miotti D, Risso A, et al: Percutaneous arthrodesis of sacro-iliac joint: a pilot study. *J. Neurosurg. Sci.* 2013; **57**: 297–301.
25. Sachs D and Capobianco R: Minimally invasive sacroiliac joint fusion: one-year outcomes in 40 patients. *Adv. Orthop.* 2013; **2013**: 536128.
26. Schroeder JE, Cunningham ME, Ross T, et al: Early Results of Sacro–Iliac Joint Fixation Following Long Fusion to the Sacrum in Adult Spine Deformity. *Hosp. Spec. Surg. J.* 2013; **10**: 30–35.
27. Cross W, et al: Minimally Invasive Sacroiliac Joint Fusion: 2-Year Radiographic and Clinical Outcomes with a Principles-Based SIJ Fusion System. *TOOJ*, 2018, 12, 7-16.
28. Vanaclocha-Vanaclocha V, Verdú-López F, Sánchez-Pardo, M, et al: Minimally Invasive Sacroiliac Joint Arthrodesis: Experience in a Prospective Series with 24 Patients. *J. Spine* 2014; **3**: 185.
29. Kube RA and Muir JM: Sacroiliac Joint Fusion: One Year Clinical and Radiographic Results Following Minimally Invasive Sacroiliac Joint Fusion Surgery. *Open Orthop. J.* 2016; **10**. Available at: <https://www.benthamopen.com/ABSTRACT/TOORTHJ-10-679>.
30. Rappoport LH, Luna IY and Joshua G: Minimally Invasive Sacroiliac Joint Fusion Using a Novel Hydroxyapatite-Coated Screw: Preliminary 1-Year Clinical and Radiographic Results of a 2-Year Prospective Study. *World Neurosurg.* 2017; **101**: 493–497.
31. Kancherla VK, McGowan SM, Audley BN, et al: Patient Reported Outcomes from Sacroiliac Joint Fusion. *Asian Spine J.* 2017; **11**: 120–126.

32. Heiney J, Capobianco R and Cher D: A systematic review of minimally invasive sacroiliac joint fusion utilizing a lateral transarticular technique. *Int. J. Spine Surg.* 2015; **9**: Article 40.
33. Lingutla KK, Pollock R and Ahuja S: Sacroiliac joint fusion for low back pain: a systematic review and meta-analysis. *Eur. Spine J.* 2016; **25**: 1924–31.
34. Zaidi HA, Montoure AJ and Dickman CA: Surgical and clinical efficacy of sacroiliac joint fusion: a systematic review of the literature. *J. Neurosurg. Spine* 2015; **23**: 59–66.
35. Dengler J, Duhon B, Whang P, et al: Predictors of Outcome in Conservative and Minimally Invasive Surgical Management of Pain Originating from the Sacroiliac Joint: A Pooled Analysis. *Spine* 2017; **42**: 1664–1673 [Epub March 27, 2017].
36. Cher DJ, Frasco MA, Arnold RJ, et al: Cost-effectiveness of minimally invasive sacroiliac joint fusion. *Clin. Outcomes Res.* 2016; **8**: 1–14.
37. Rudolf L and Capobianco R: Five-year clinical and radiographic outcomes after minimally invasive sacroiliac joint fusion using triangular implants. *Open Orthop. J.* 2014; **8**: 375–383.
38. Petersen T, Laslett M and Juhl C: Clinical classification in low back pain: best-evidence diagnostic rules based on systematic reviews. *BMC Musculoskelet. Disord.* 2017; **18**: 188.
39. Kennedy DJ, Engel A, Kreiner DS, et al: Fluoroscopically Guided Diagnostic and Therapeutic Intra-Articular Sacroiliac Joint Injections: A Systematic Review. *Pain Med. Malden Mass* 2015; **16**: 1500–1518.
40. Engel A, MacVicar J and Bogduk N: A philosophical foundation for diagnostic blocks, with criteria for their validation. *Pain Med. Malden Mass* 2014; **15**: 998–1006.
41. Polly D, Cher D, Whang PG, et al: Does Level of Response to SI Joint Block Predict Response to SI Joint Fusion? *Int. J. Spine Surg.* 2016; **10**: Article 4.
42. Polly D and Cher D: Ignoring the sacroiliac joint in chronic low back pain is costly. *Clin. Outcomes Res.* 2016; **8**: 23–31.
43. Khurana A, Guha AR, Mohanty K, et al: Percutaneous fusion of the sacroiliac joint with hollow modular anchorage screws: clinical and radiological outcome. *J. Bone Joint Surg. Br.* 2009; **91**: 627–631.

Appendix

Polly et al. – INSITE study.¹⁶ This is a randomized trial of minimally invasive SIJ fusion vs. non-surgical treatment in 148 patients with chronic SIJ pain. Patients were selected on the basis of a standard diagnostic algorithm that included history, physical exam, diagnostic SIJ block and imaging to rule out other prominent causes of low back pain. The study showed marked improvements in pain, disability and quality of life in the SIJ fusion group but very little, if any, improvement in the non-surgical groups. A figure showing SIJ pain and ODI is shown below.

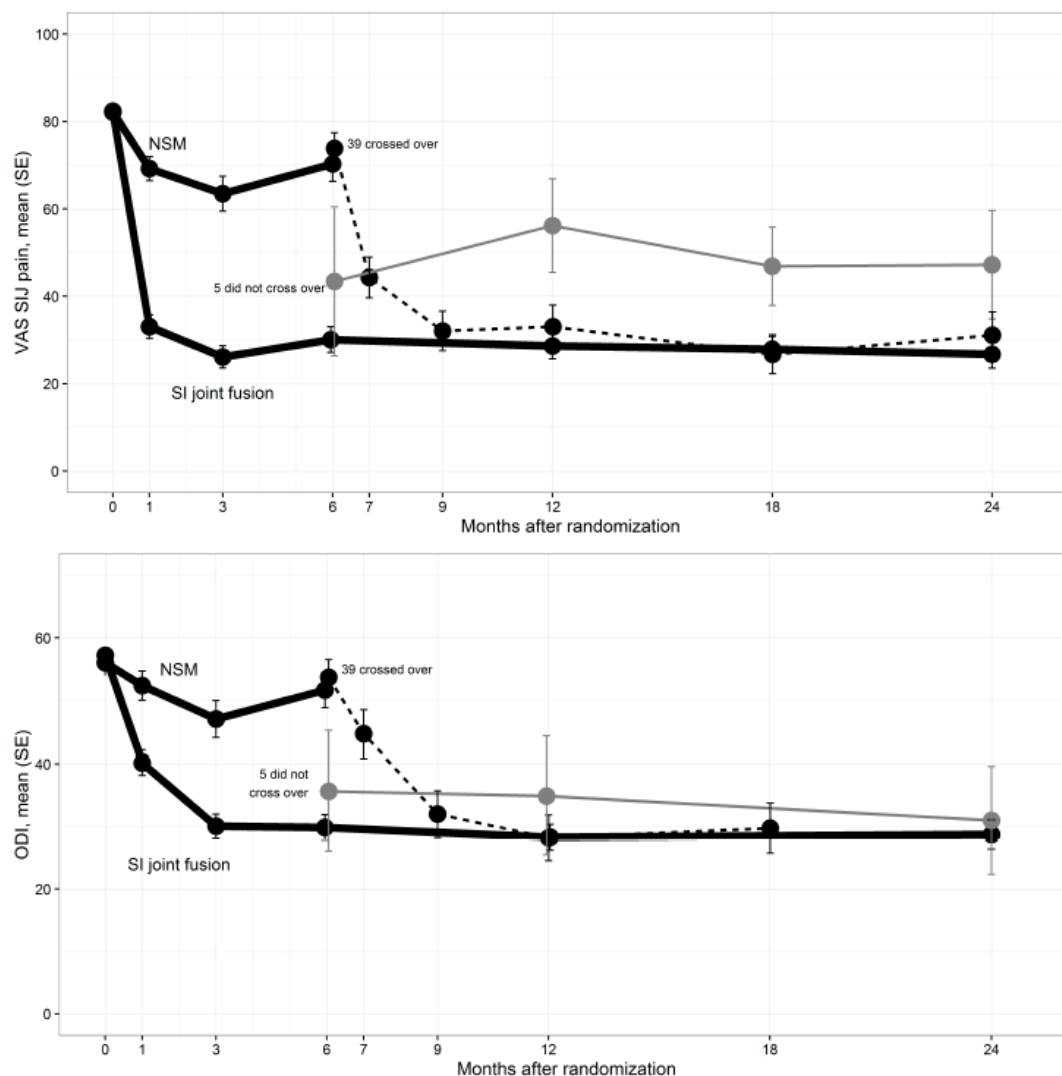
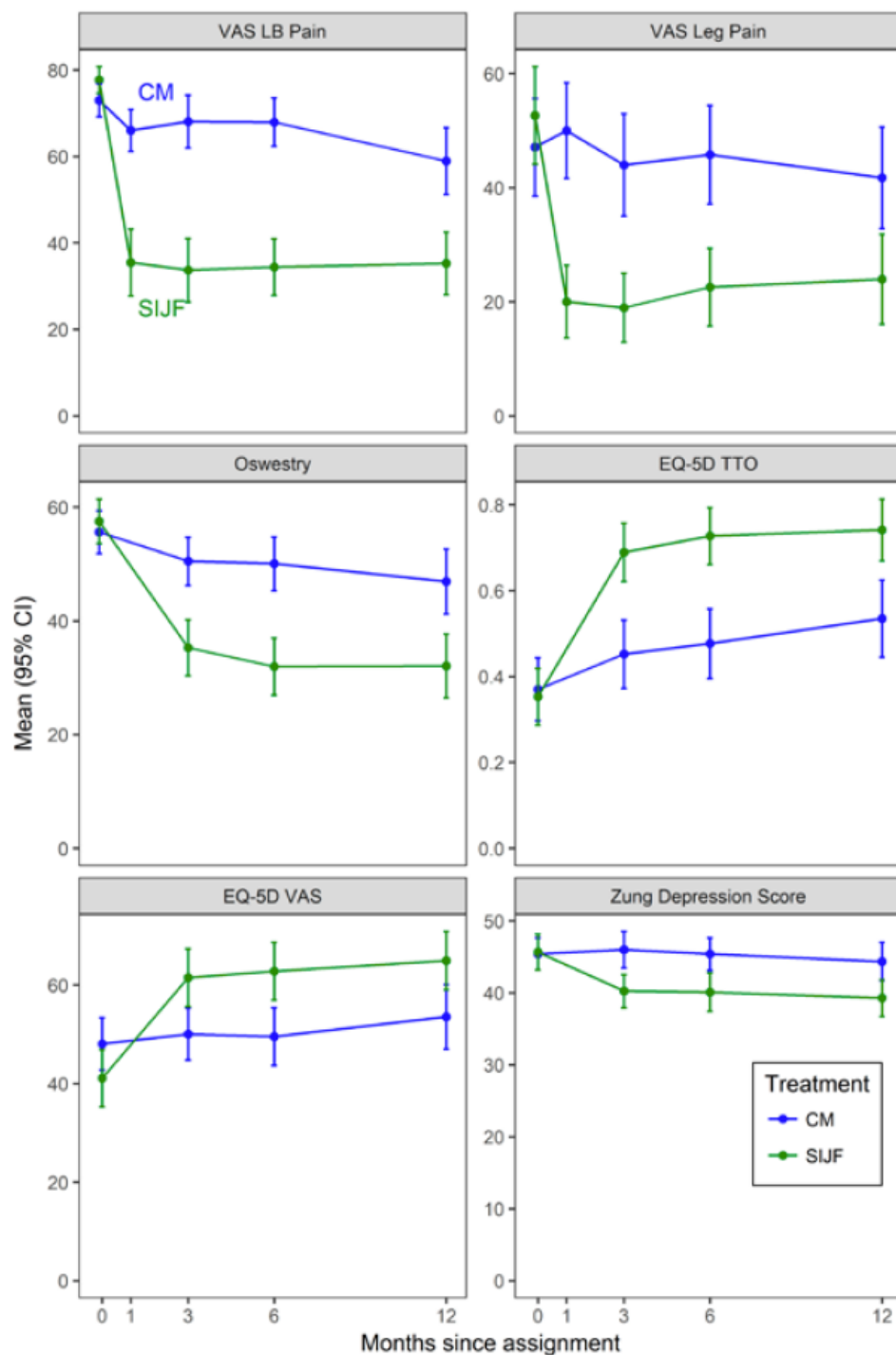


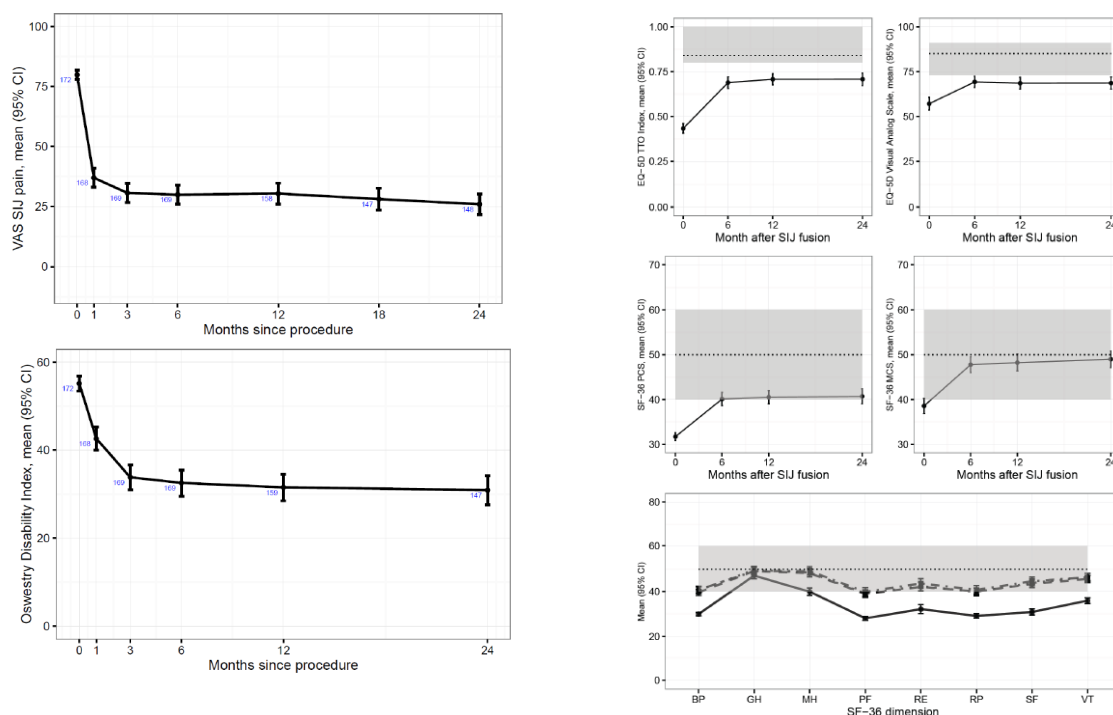
Fig. 2. Mean SIJ pain by visit (top). Dark thick lines are those assigned to NSM or SIJF. Dotted line indicates NSM subjects who crossed over to surgery. Thin gray line indicates those who did not cross over to surgery. Mean Oswestry Disability Index by visit (bottom) is shown similarly.

Dengler et al. – iMIA study.¹⁷ This is a randomized trial of minimally invasive SIJ fusion vs. conservative management conducted in Europe. Similar to Polly et al., the study showed

marked improvements in pain, disability and quality of life. The graph below from this study also shows improvement in Zung depression scores in the SIJ fusion group but not the conservative group.

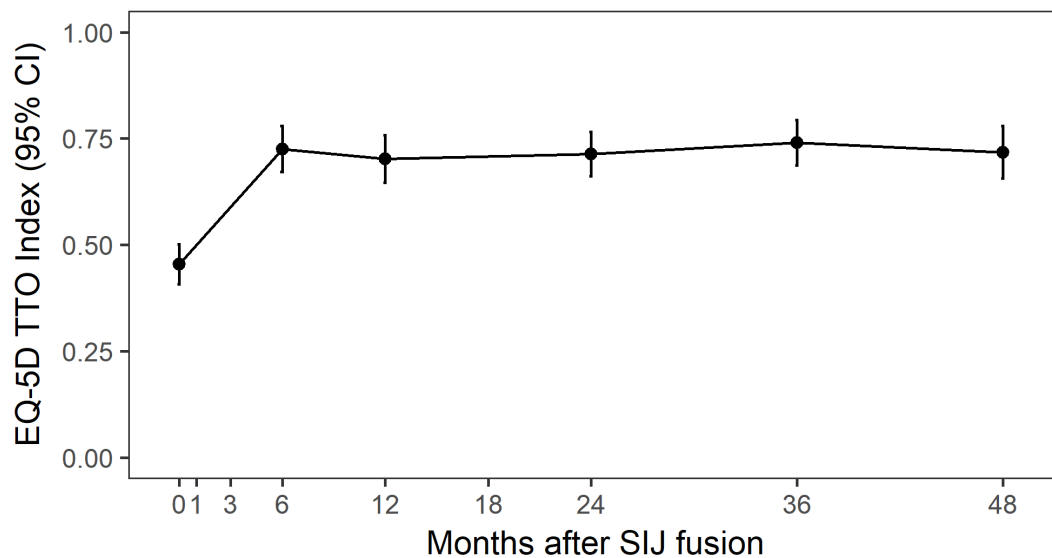
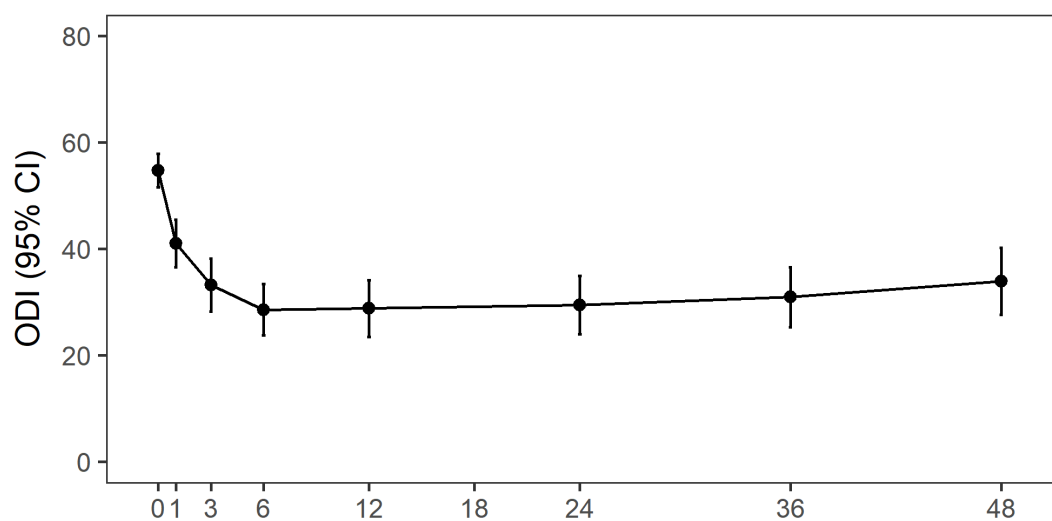
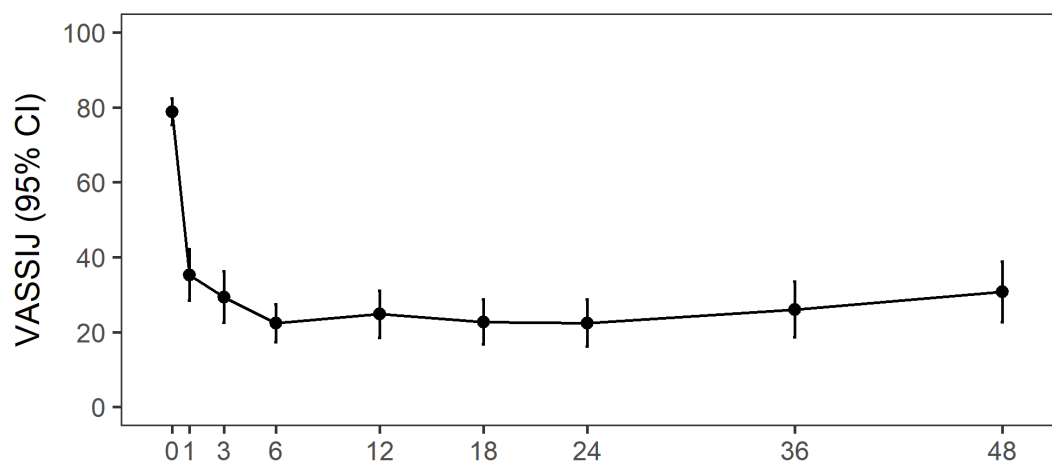


Duhon et al. – SIFI study.¹⁸ This is a single-arm multicenter study of minimally invasive SIJ fusion. Patients were recruited using identical eligibility criteria as Polly et al (INSITE). The study shows improvement in SIJ pain, Oswestry Disability Index and quality of life measures (SF-36 and EQ-5D).

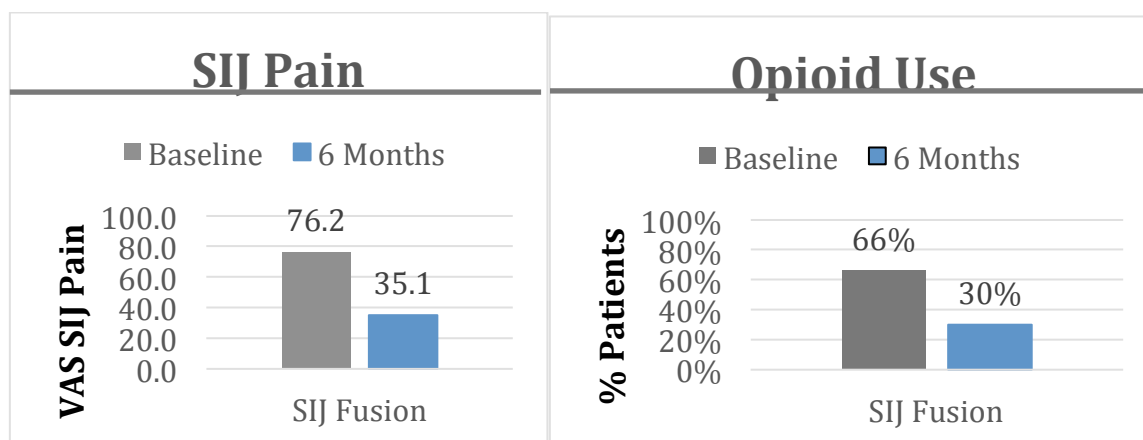


Long-term follow-up from the two US clinical trials (Polly/INSITE and Duhon/SIFI) is currently under consideration for publication in the ISASS peer-reviewed journal. 3-year data in 97 patients and 4-year data in 57 patients (see below) show continued improvement in pain and disability.

Subjects with 4 year data

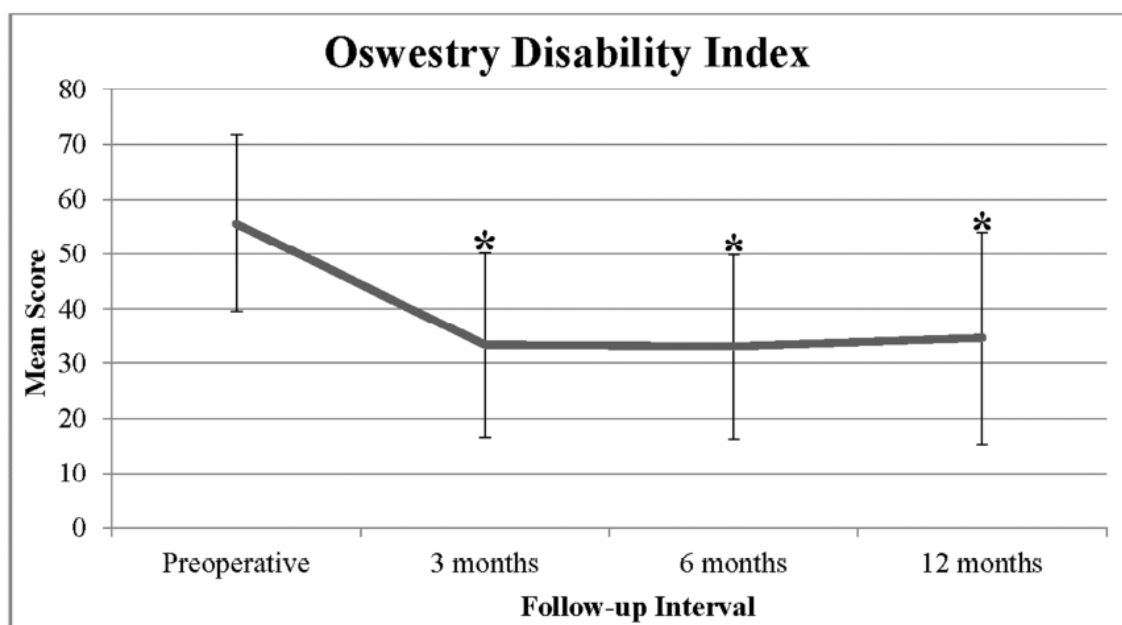


Araghi et al. – EVoluSIon study.¹⁹ This is a single-arm multicenter study of minimally invasive SIJ fusion. Patients were recruited based on standard diagnostic criteria including conservative care, physical exam, and diagnostic SIJ block. The study shows significant improvement in SIJ pain, Oswestry Disability Index and quality of life measures (SF-36 and EQ-5D), all while decreased use of opioids by 55% six months after the procedure. A figure showing SIJ pain improvement and opioid reduction is shown below.



Cross et al.²⁷ This is a single-arm multicenter study of 19 patients undergoing SIJ fusion with joint decortication. Patients showed marked improvement in pain and high rates of bony fusion of the SI joint.

Rappoport et al.³⁰ This is a single-arm case series of 32 patients undergoing SIJ fusion using a hydroxyapatite-coated screw. Patients showed improvement in pain and disability.



Kancherla et al.³¹ This is a single-arm study of 45 patients who underwent minimally invasive SIJ fusion using two different fusion devices. The authors showed a reduction in opioid use, high satisfaction rates and a high rate of improvement in pain and quality of life.

Kube et al.²⁹ This is a single-arm study of 18 patients who underwent SIJ fusion using decortication and threaded implants. The fusion rate at one year was 88% and there was significant improvement in pain and disability.

Khurana et al.⁴³ This is a single-arm study of 15 patients who underwent SIJ fusion using hollow modular anchor screws. With mean follow-up of 17 months, SF-36 and Majeed scores improved markedly.

Vanaclocha et al.²¹ This is retrospective comparative case series of patients with carefully diagnosed SIJ pain who underwent either SIJ fusion, RF ablation of the lateral branches of the sacral nerve roots (termed SI denervation) or conservative management. Patients who underwent SIJ fusion had marked improvement in pain and disability; patients who underwent conservative management had no improvement. Moreover, opioid use increased in conservative management patients.

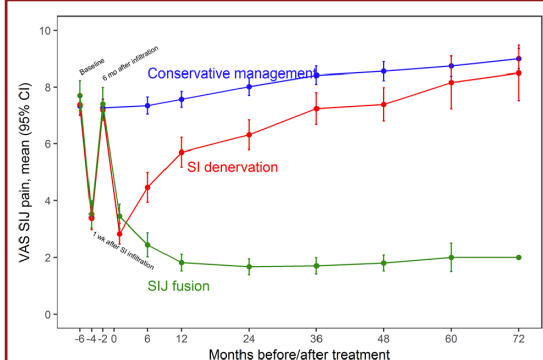


FIGURE 3. Mean (95% CI) SIJ pain assessed with VAS by treatment and follow-up duration. The small numbers show the number of patients at each visit. SI, sacroiliac; SIJ, sacroiliac joint; VAS, visual analog scale.

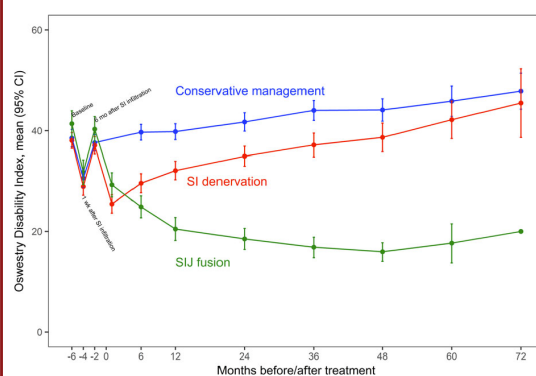


FIGURE 4. Mean (95% CI) Oswestry Disability Index by treatment and follow-up duration. The small numbers show the number of patients at each visit. SI, sacroiliac; SIJ, sacroiliac joint.